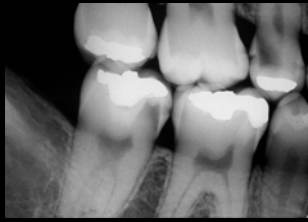
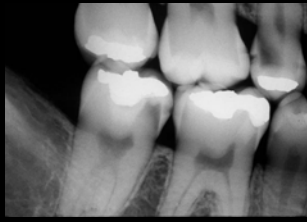
LESÕES DO ORGÃO DENTÁRIO / ASPECTOS RADIOGRÁFICOS - Prancha 1

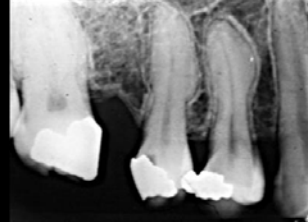1



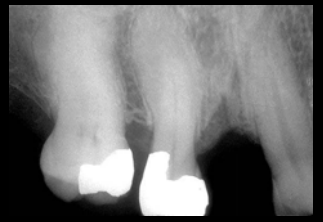2



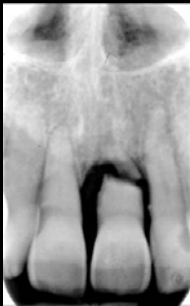3



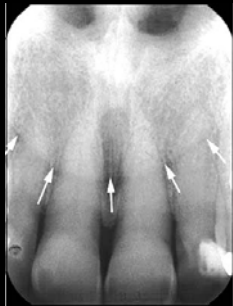4



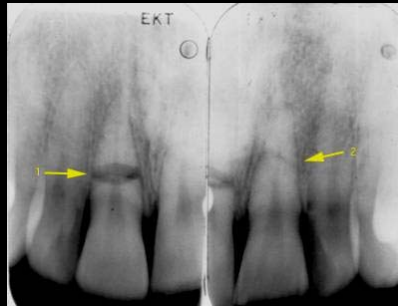5



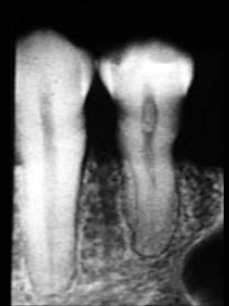6



7

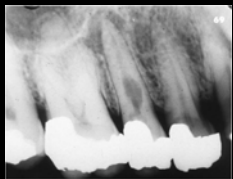


8

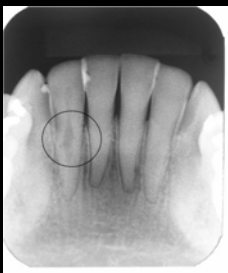


9

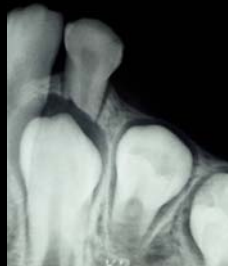10



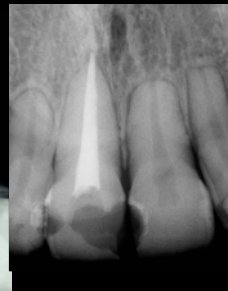
11



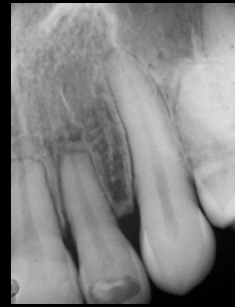12



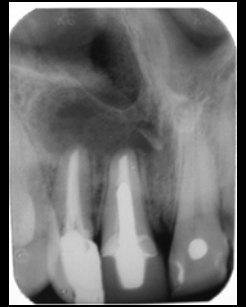13



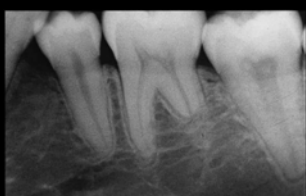14



15



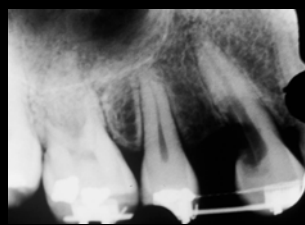
16



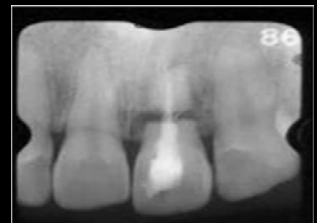17



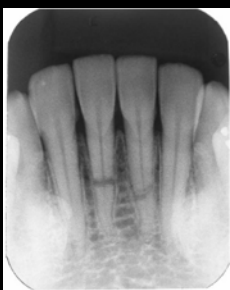18



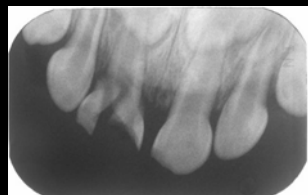19



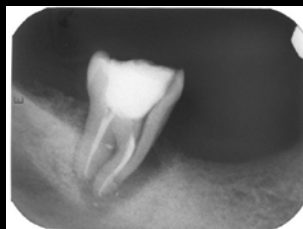20



21



22



23

