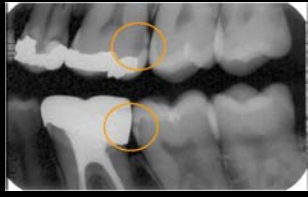
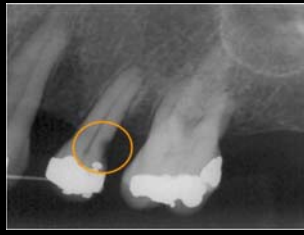

**LESÕES DO ORGÃO DENTÁRIO / ASPECTOS RADIOGRÁFICOS - Prancha 2**

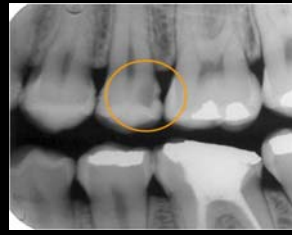1



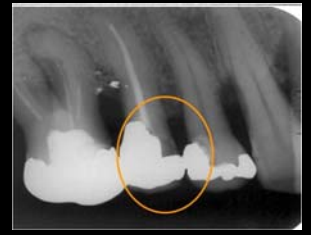2



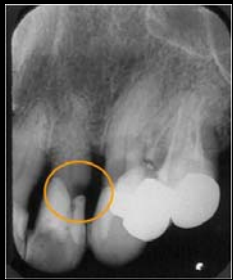3



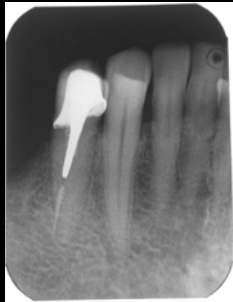4



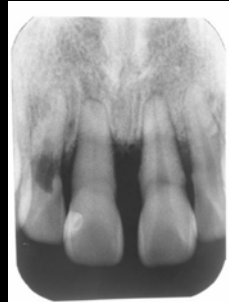5



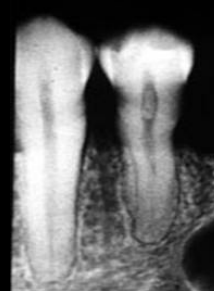6



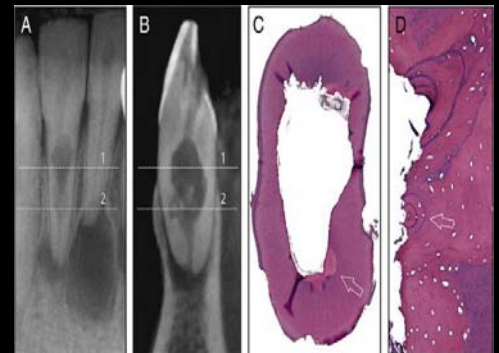
7



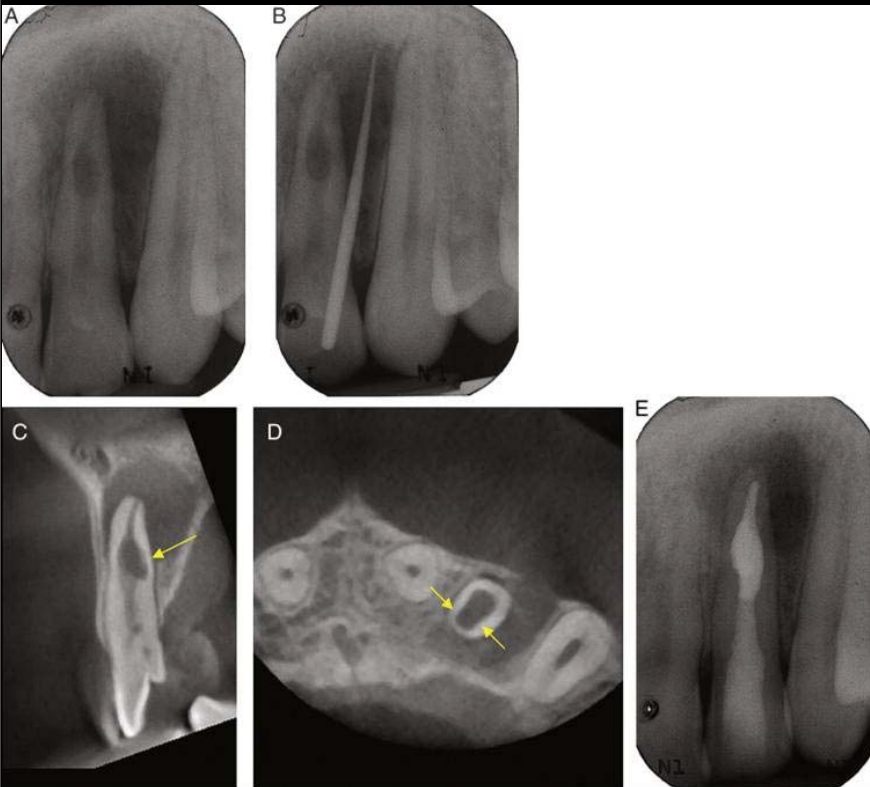
8



10



9



11

